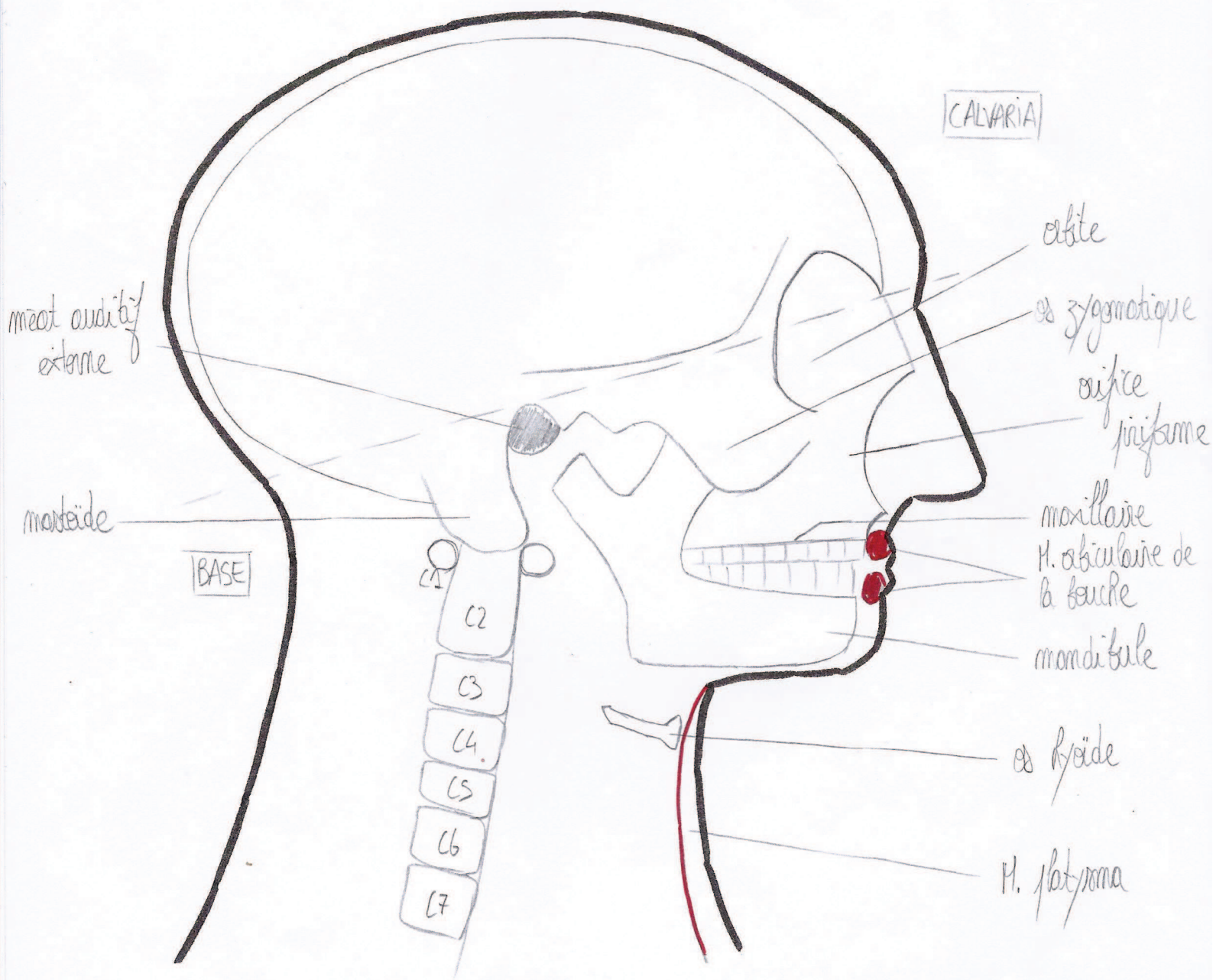
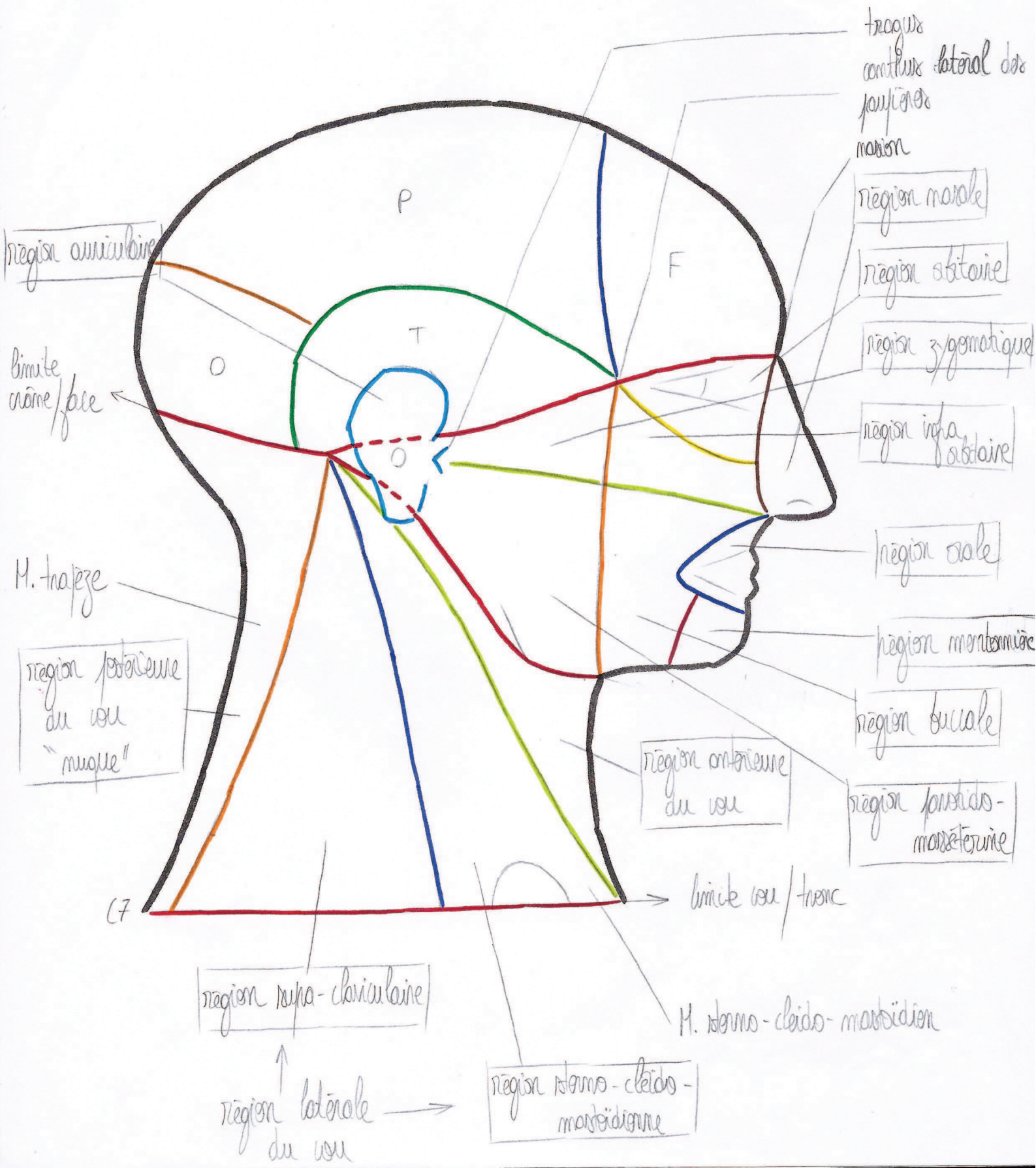


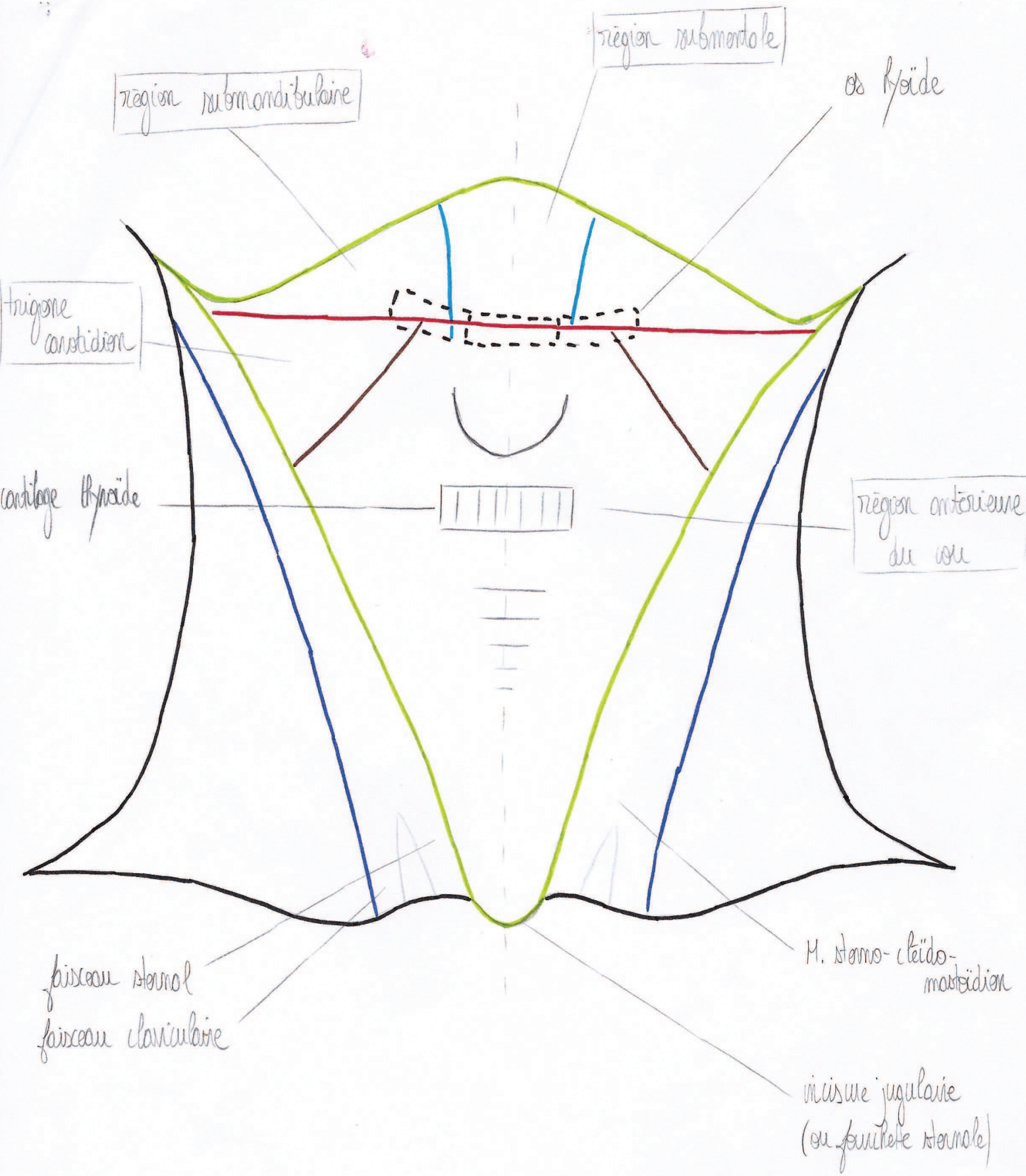
Organisation générale du squelette



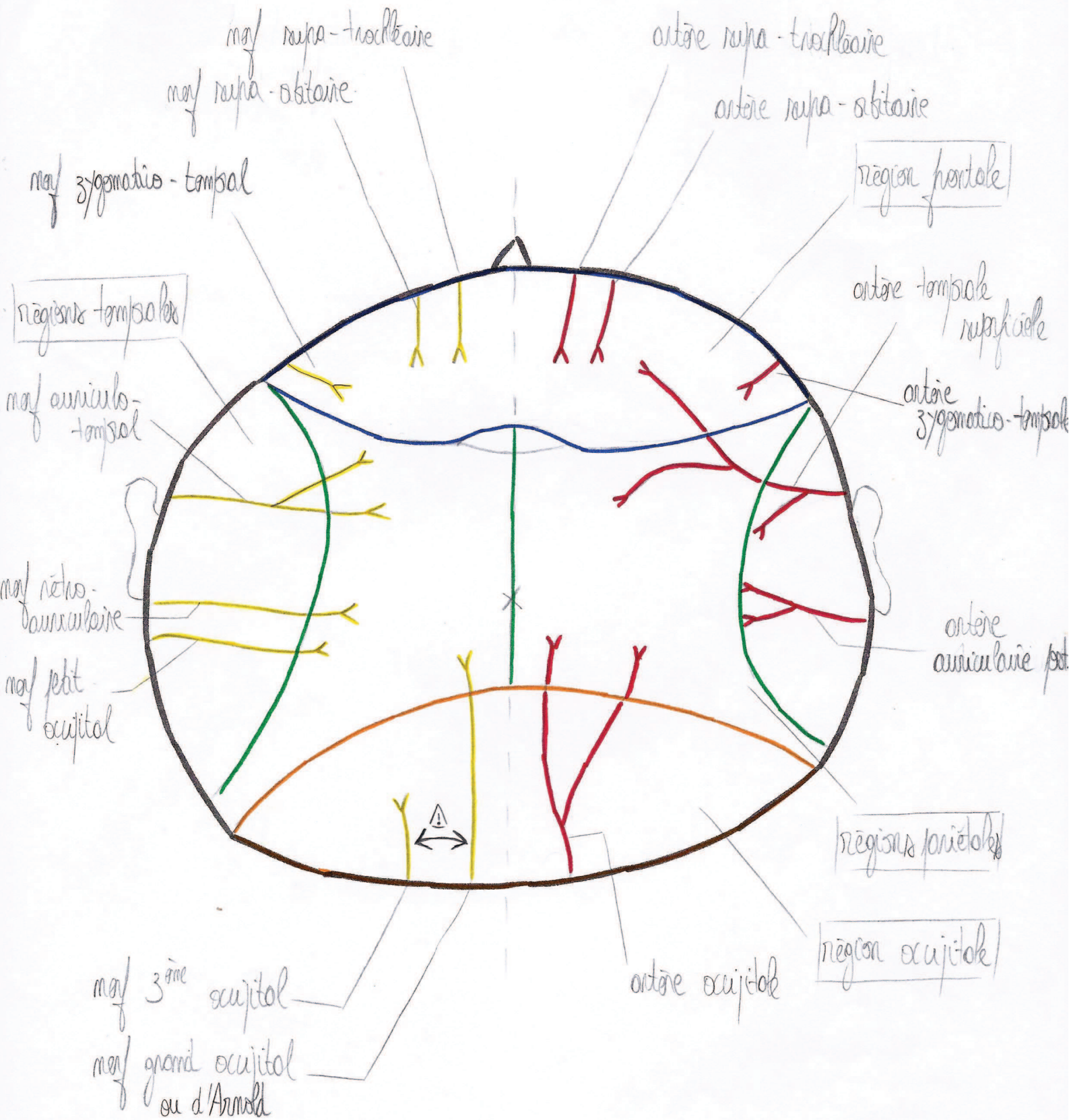
des régions superficielles de la tête et du cou



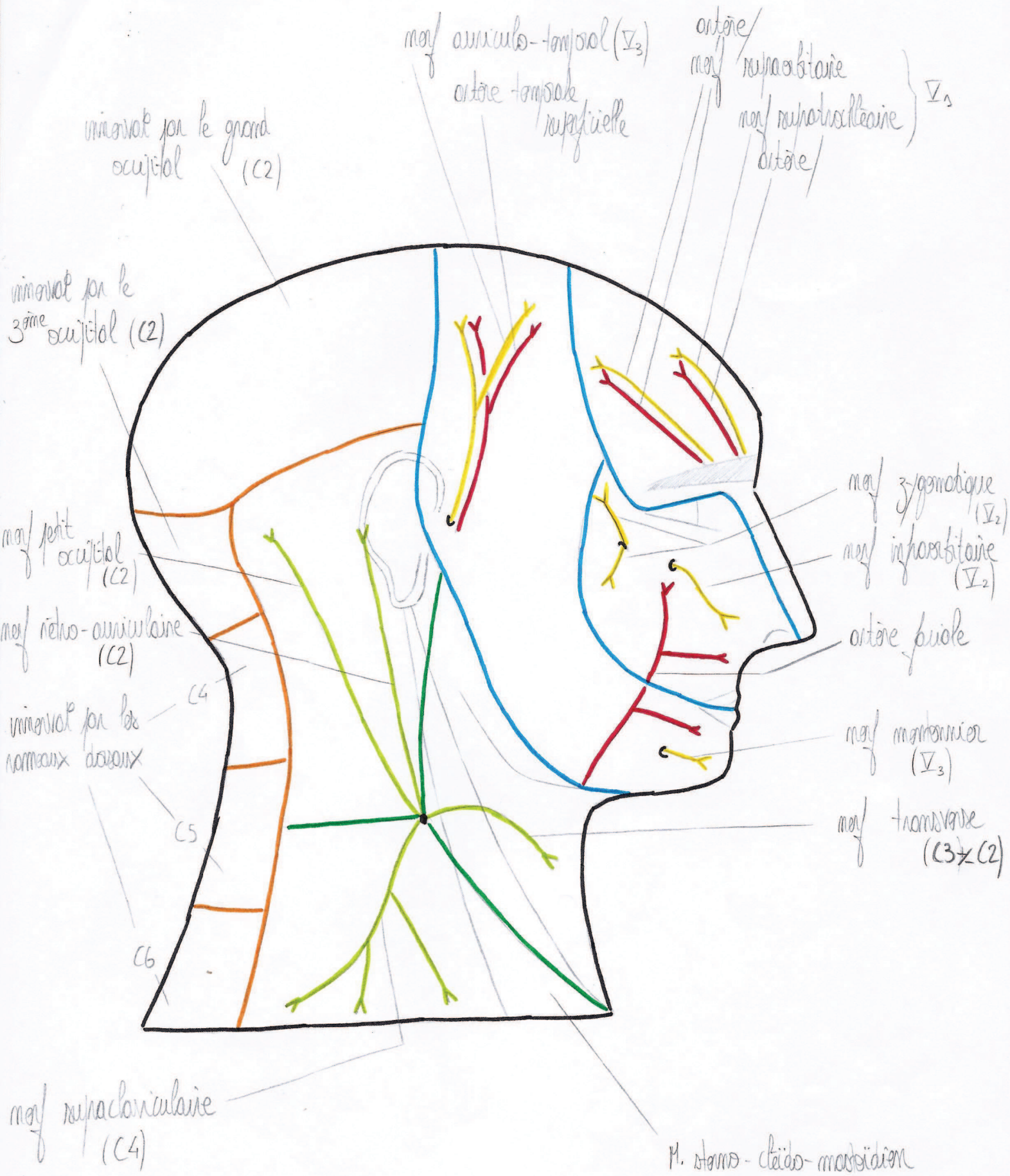
des régions antérieures superficielles du cou



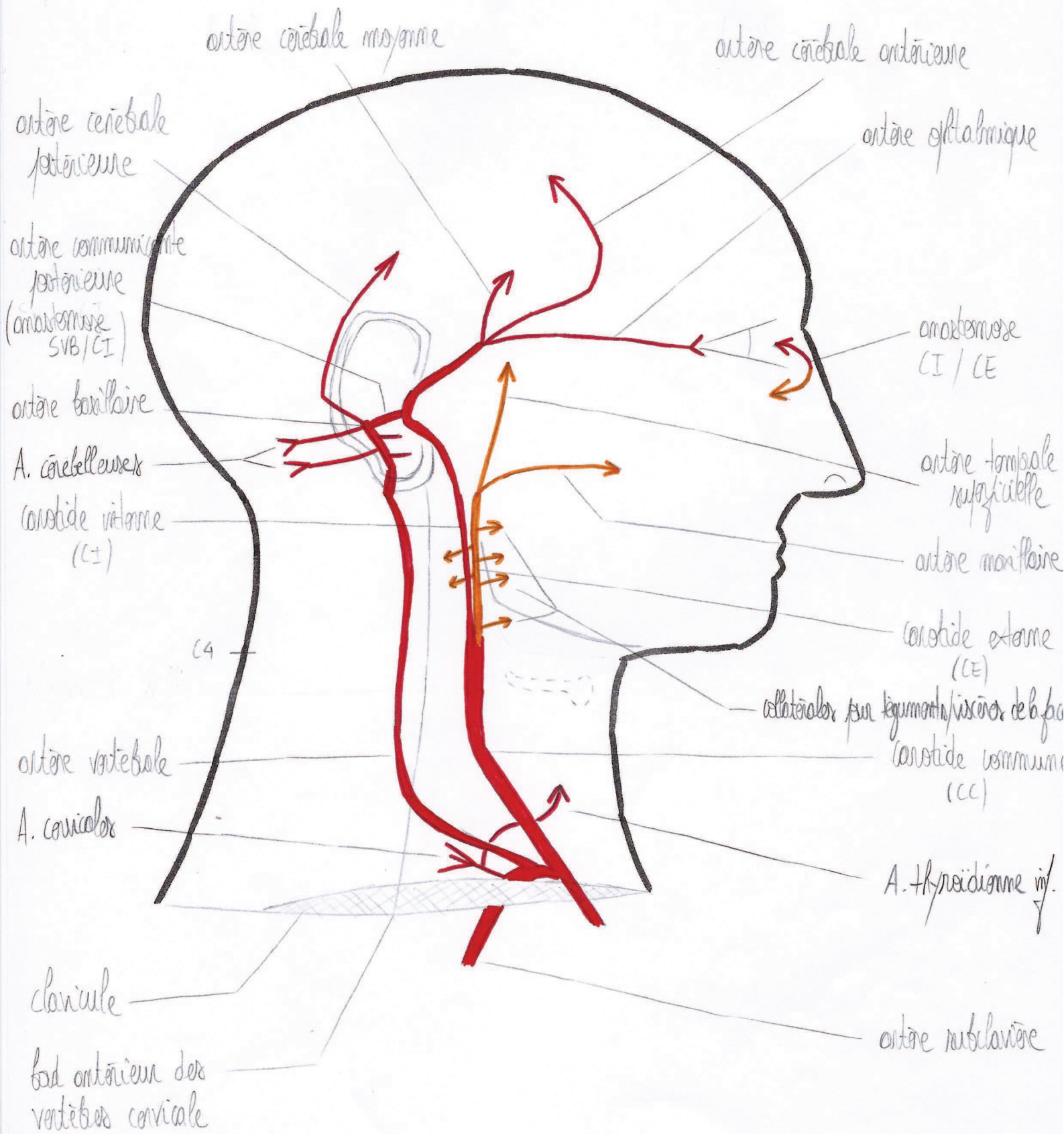
des régions superficielles du crâne



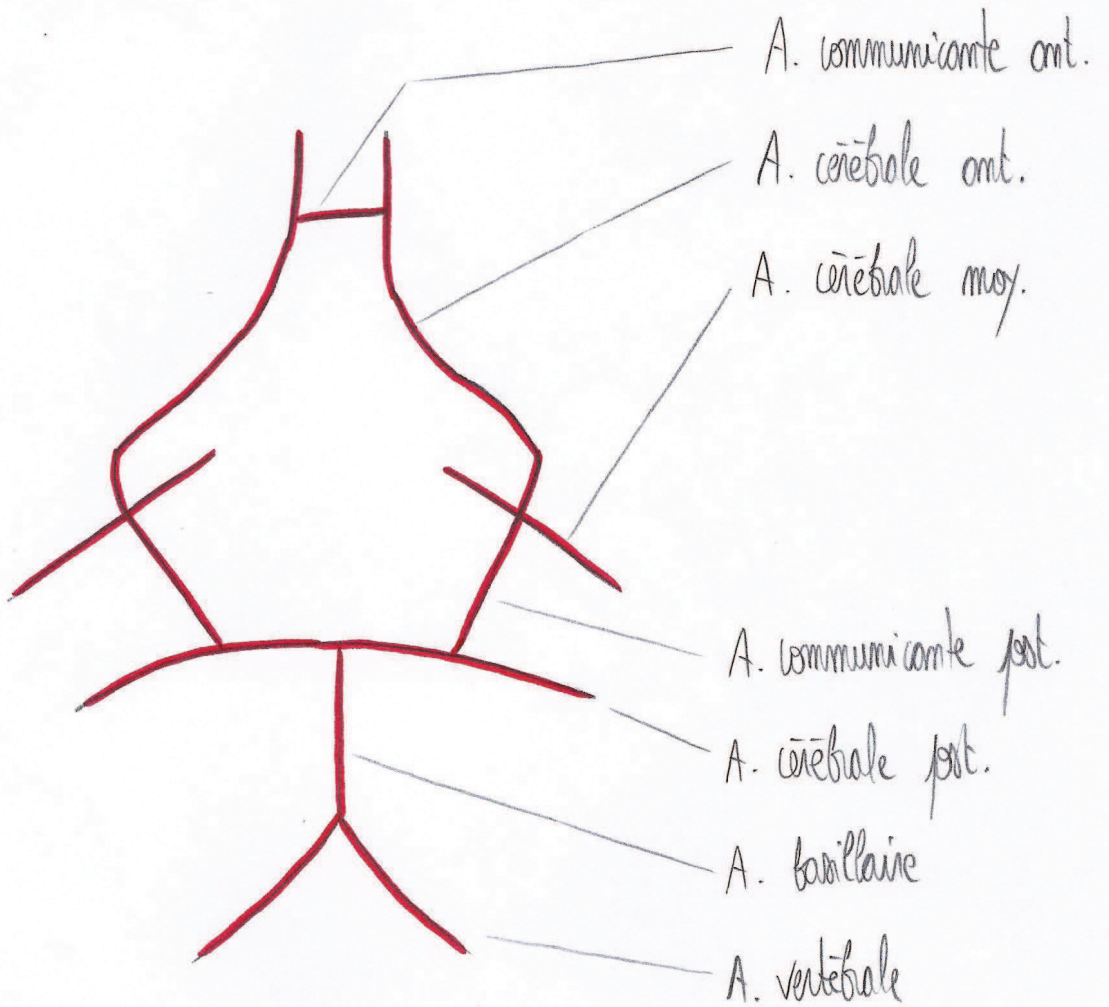
Immervation des teguments de la face et du cou



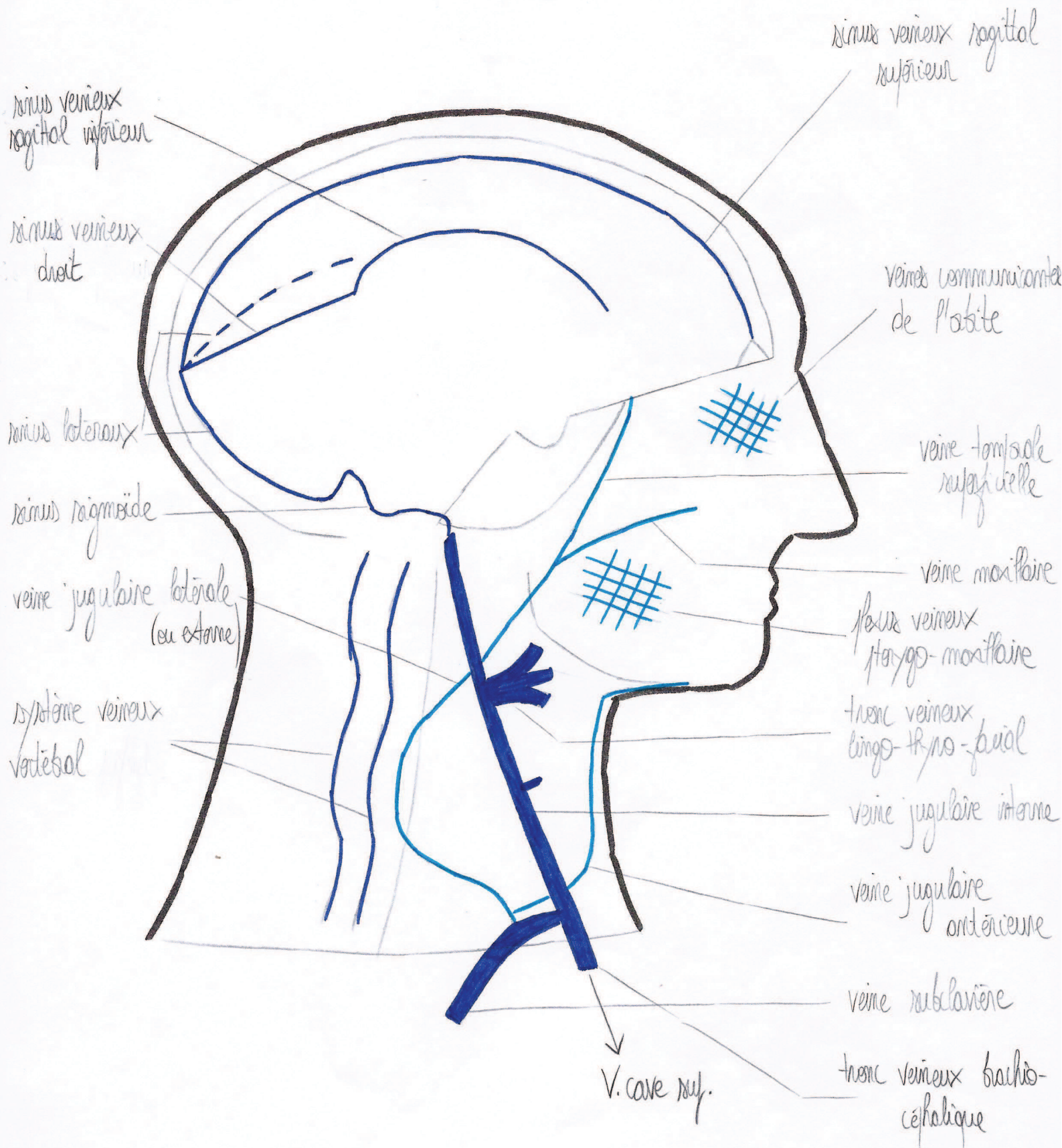
Organisation générale des structures artérielles



de poligone de Willis



Organisation générale des structures veineuses



Organisation générale des structures lymphatiques

